

EPIDURAL ANESTHESIA – WHEN BAD THINGS HAPPEN

Charles A. Reese, Ph.D., CRNA

Disclosure

No relevant relationship with any commercial interest

No relevant financial relationships that would bias or compromise the presentation of these materials

No off-label use of medications

- ✓ 10:30 AM: (~+30")
 - ✓ MDA called back
 - ✓ Sensory block ~"collar bone"
- ✓ Stops infusion
 - ✓ "Lack of Concern" ...
 - ✓ Removes catheter ... "wait til it wears off"

- ✓ 28 yo, G1, P0, term
- ✓ IOL
- ✓ AM admit... expectant PM delivery
- ✓ Wednesday, 7:05 AM
 - ✓ VS, LABS ... WNL
 - ✓ 8:11 AM: miso/oxytocin augmentation

- ✓ 12:20 PM: repeats LEA
 - ✓ Documented problems with 2nd placement ('wet tap'?)
 - ✓ "Doesn't work at all"
 - ✓ MDA busy
 - ✓ pager, phone, called by nurses
 - ✓ "... wait for evaluation"
- ✓ Notes catheter disconnected from infusion tubing
 - ✓ ?? Timeline
 - ✓ Reconnects the tubing
 - ✓ "OK", leaves
- ✓ "party atmosphere"
 - ✓ ~8 visitors in room (video)



- ✓ 9:55 AM:
 - ✓ LEA placed
 - ✓ Documented problems with placement ...
- ✓ Immediate onset ...
 - ✓ "Blotchy face"
 - ✓ "Lethargic"
 - ✓ "Heavy chest"

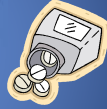"Wet Tap" ?
"Subdural Drug" ?

- ✓ 3:06 PM:
 - ✓ 9# 4oz male
 - ✓ Vaginal laceration ... repaired

- ✓ Later that afternoon
 - ✓ ... c/o 'headache'
 - ✓ "No RN help ~5-6 hours"



- ✓ Thursday, 12:40 AM:
 - ✓ Seen by MD (house staff?)
 - ✓ Benadryl ... "calm down"



- ✓ 2:00 AM:
 - ✓ "pain ... crying"
 - ✓ "don't want to die"
 - ✓ IV fluids
 - ✓ Disoriented ... "seizure" ... rips out IVs
- ✓ Husband seeks help
- ✓ Sudden increase in staff

- ✓ 10:00 PM:
 - ✓ sleeping
- ✓ 11:30 PM:
 - ✓ "eyes swelling"
 - ✓ "severe headache / neck pain"
 - ✓ "nervous"
- ✓ OB notified ... phone order Percocet
 - ✓ Presumptive dx = "migraine"
 - ✓ ~45" ... no relief
 - ✓ "no attention from staff"



- ✓ 2:40 AM:
 - ✓ Transferred to ICU
 - ✓ Presumptive dx: chemical meningitis
 - ✓ Dilated pupils
 - ✓ LP: "cloudy" ... "shot out of needle"
- ✓ 4:00 AM:
 - ✓ Infant to NICU
 - ✓ Antibiotics
 - ✓ Isolation

Baer, ET. 2006 Post-Dural Puncture Bacterial Meningitis. Anesthesiology V105 (2) Aug. 381-392

- ✓ 1:30 AM:
 - ✓ Fever increasing (101.6°F)
 - ✓ OB again notified
 - ✓ Does not come to hospital
 - ✓ Antibiotic ordered

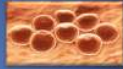


- ✓ ?? AM:
 - ✓ Life support
 - ✓ CT: Massive brain damage
 - ("no intracerebral circulation")
 - ✓ "not wake up" ... vegetative state
 - ✓ Died ... 60 hr after admission!

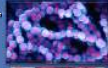Baer, ET. 2006 Post-Dural Puncture Bacterial Meningitis. Anesthesiology V105 (2) Aug. 381-392

✓ LP culture results:

- ✓ Staphylococcus simulans (CSF culture) **



- ✓ Streptococcus salivarius (blood culture) **



- ✓ both sensitive to routine antibiotics

** Report not available until 3-4 days

Nucleic Acid Amplification Test (NAAT)

... probes & rapid ID kits available (~4hr)

... use when meningitis concern!

(Staph. aureus, Streptococcus, Enterococcus,

Pseudomonas, Klebsiella, Citrobacter.)



Base, ET, 2004

2004

2004

2004

2004

2004

2004

2004

2004

2004

2004

2004

2004

2004

2004

2004

2004

2004

2004

2004

2004

2004

2004

2004

2004

2004

2004

2004

2004

2004

2004

2004

2004

2004

2004

2004

2004

2004

2004

2004

2004

2004

2004

2004

2004

2004

2004

2004

2004

2004

2004

2004

2004

2004

2004

2004

2004

2004

2004

2004

2004

2004

2004

2004

2004

2004

2004

2004

2004

2004

2004

2004

2004

2004

2004

2004

2004

2004

2004

2004

2004

2004

2004

2004

2004

2004

2004

2004

2004

2004

2004

2004

2004

2004

2004

2004

2004

2004

2004

2004

2004

Constellation of Concerns



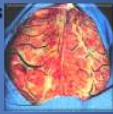
✓ Autopsy

- ✓ Cerebral bacterial meningitis

- ✓ Cerebral encephalopathy

- ✓ Diabetes insipidus

- ✓ Hyponatremia



- ✓ LP done despite coma/seizures ... brain herniation?

Base, ET, 2004 Push-Dural Pressure Bacterial Meningitis. Anesthesiology 100 (2) Aug. 381-382



- ✓ Defense argues viral infection



- ✓ "...not the result of a hospital-based infection or illness nor any specific action or lack of action on the part of ___ hospital"

- ✓ "... met the standard of care, including staffing"

Constellation of Concerns

- ✓ High block ... No block

- ✓ Technical:

- ✓ "Busy" ... phone, pager (sterile tech)

- ✓ Wet tap x 2

- ✓ Catheter disconnected

... "snaps back together"

- ✓ Visitors x 8+

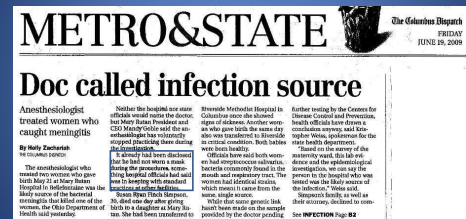- ✓ Antibiotic never given !!

Hospital Acquired Infection

- ✓ 4th largest killer
- ✓ As many deaths as AIDS, breast cancer, and auto accidents **COMBINED!**
- ✓ 1:20 patients get an infection
 - ✓ 2,000,000/year
 - ✓ 103,000 of these ... DIE!
- ✓ Hand washing is most important method prevention

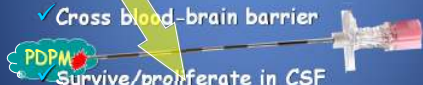

Aseptic technique



Pathogenesis of Meningitis

- ✓ Colonize host epithelium
 - ✓ Invade intravascular space
 - ✓ Cross blood-brain barrier
 - ✓ Survive/proliferate in CSF
- ~2-3 hr between bacterial inoculation and onset of symptoms



Aseptic technique



How Inoculated?

- ✓ PDPM ... very rare !! (~180 cases)
 - ✓ 2 from same neurologist
 - ✓ 2 from same neurosurgeon
 - ✓ 4 from same anesthesiologist
 - ✓ 2 from same OR (sequential cases)
- ... suggests an operator-related role!

PDPM

- ✓ *Strep. salivarius* meningitis after myelogram
 - ✓ Compared pt. CSF isolate with neurologist & assistant
 - ✓ DNA matched ONLY the neurologist
- ✓ *Staph. aureus* epi. abscess after epidural
 - ✓ Compared pt. CSF isolate with 9 midwives, 2 GYN, & anesthesiologist
 - ✓ matched ONLY the anesthesiologist

* Wenzel R, van Belkum A, Schellekens W. Nosocomial meningitis by Streptococcus salivarius following lumbar puncture (Letter). J Hosp Infect 1992; 20: 249-50.
 * Tschann W, Lueger PH, Schindler FJ. Three cases of bacterial meningitis after spinal and epidural anesthesia. J Clin Microbiol Infect Dis 1992; 21:45-7

PDPM

- ✓ Mega-analysis ... 179 cases
- ✓ 23% skin organisms
- ✓ 76% mouth/upper airway organisms**
 - ... supports concept of aerosolized droplet contamination
 - ... even worse with recent URI

**** becoming antibacterial resistant!**

Prevention



Prevention

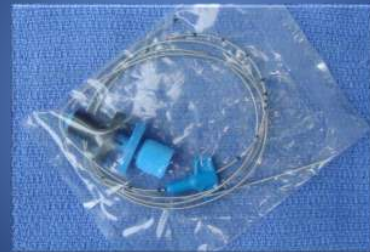

Prevention

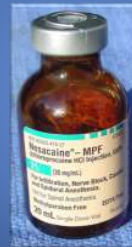

Prevention





A photograph of an astronaut in a white spacesuit standing on the lunar surface. The astronaut is wearing a helmet with a reflective visor and is holding a small object in their gloved hand. The background shows the dark, cratered surface of the Moon under a bright sky.



**Position Statement
Number 2.13
Safe Practices for Needle
and Syringe Use**

[illegible]

Propofol - Hep C Insurance Fraud

Re-used colonoscopes

Ordered re-use
Syringes/Propofol

50,000 patients
9 Hep C, 2 dead

Life
(18 yr parole)

